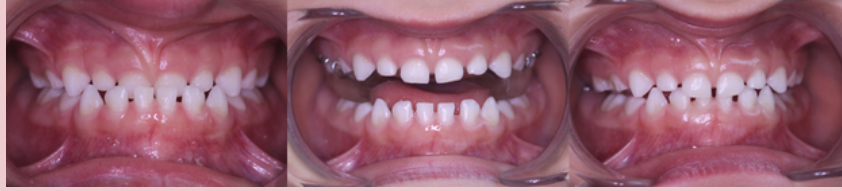

CLASS III :
ANTERIOR CROSSBITE
Dr. Ben Younes-Uzan

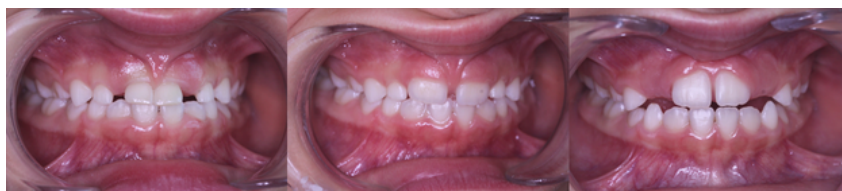

THIS IS A CLASS III CLINICAL CASE (ANTERIOR INVERTED CROSSBITE).

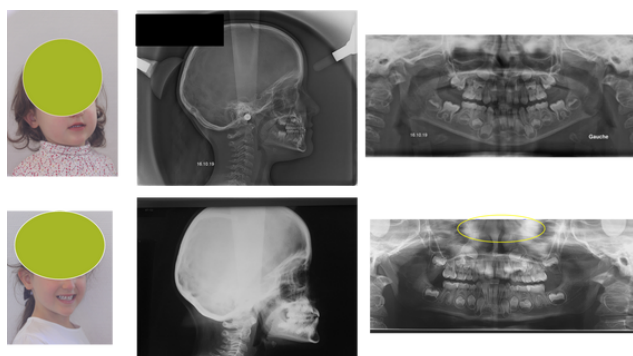
TO REMEDY THIS, WE UNDERTOOK A THREE-DIMENSIONAL ORTHOPEDIC EXPANSION OF THE MAXILLA WITH AN APPLIANCE CARRYING MOLAR ELEVATIONS.

SUBSEQUENTLY, DUE TO THE POOR ORIENTATION OF THE UPPER CANINES, WE CONTINUED THE EXPANSION HOPING FOR THEIR STRAIGHTENING WITHOUT ELEVATION.

THE FROGGY MOUTH APPLIANCE ALLOWED MANDIBULAR ADAPTATION TO MAXILLARY EXPANSION.



THE PATIENT'S FACE IS NOW MUCH MORE HARMONIOUS AND SHE SEEMS TO BREATHE MORE EASILY THROUGH HER NOSE. TREATMENT PROGRESS CAN BE ASSESSED SIMPLY BY OBSERVING THE FACE, EVEN IF THE EYES ARE CONCEALED. IT IS APPROPRIATE TO FOLLOW THE EVOLUTION OF THIS CASE OVER SEVERAL YEARS, GIVEN THAT THE PATIENT IS YOUNG.



FROGGY MOUTH